

# PEDIATRICS®

OFFICIAL JOURNAL OF THE AMERICAN ACADEMY OF PEDIATRICS

## **Alternating Hemiplegia of Childhood: Early Characteristics and Evolution of a Neurodevelopmental Syndrome**

Matthew T. Sweney, Kenneth Silver, Marion Gerard-Blanluet, Jean-Michel Pedespan, Francis Renault, Alexis Arzimanoglou, Mylynda Schlesinger-Massart, Aga J. Lewelt, Sandra P. Reyna and Kathryn J. Swoboda

*Pediatrics* 2009;123:e534-e541

DOI: 10.1542/peds.2008-2027

The online version of this article, along with updated information and services, is located on the World Wide Web at:

<http://www.pediatrics.org/cgi/content/full/123/3/e534>

PEDIATRICS is the official journal of the American Academy of Pediatrics. A monthly publication, it has been published continuously since 1948. PEDIATRICS is owned, published, and trademarked by the American Academy of Pediatrics, 141 Northwest Point Boulevard, Elk Grove Village, Illinois, 60007. Copyright © 2009 by the American Academy of Pediatrics. All rights reserved. Print ISSN: 0031-4005. Online ISSN: 1098-4275.

American Academy of Pediatrics

DEDICATED TO THE HEALTH OF ALL CHILDREN™



# Alternating Hemiplegia of Childhood: Early Characteristics and Evolution of a Neurodevelopmental Syndrome

Matthew T. Sweney, MD<sup>a</sup>, Kenneth Silver, MD<sup>b</sup>, Marion Gerard-Blanluet, MD<sup>c</sup>, Jean-Michel Pedespan, MD<sup>d</sup>, Francis Renault, MD<sup>e</sup>, Alexis Arzimanoglou, MD<sup>f</sup>, Mylynda Schlesinger-Massart, MD<sup>g</sup>, Aga J. Lewelt, MD<sup>h</sup>, Sandra P. Reyna, MD<sup>a</sup>, Kathryn J. Swoboda, MD<sup>a</sup>

<sup>a</sup>Departments of Neurology and Pediatrics, <sup>b</sup>Department of Physical Medicine and Rehabilitation, University of Utah School of Medicine, Salt Lake City, Utah; <sup>b</sup>Departments of Pediatrics and Neurology, University of Chicago Hospitals, Chicago, Illinois; <sup>c</sup>Clinical Genetics Unit, Department of Medical Genetics, Assistance Publique-Hôpitaux de Paris, Robert Debré University Hospital, Paris, France; <sup>d</sup>Department of Pediatrics, Bordeaux University Hospital, Bordeaux, France; <sup>e</sup>Clinical Neurophysiology Unit, Armand-Trousseau Hospital, Paris, France; <sup>f</sup>Department of Pediatric Epilepsy, Sleep and Clinical Neurophysiology and Institute for Children and Adolescents With Epilepsy-Institut Des Épilepsies de l'Enfant et de l'Adolescent, University Hospitals of Lyon and Institut National de la Santé de la Recherche Médicale, Dynamique Cérébrale et Cognition, Lyon, France; <sup>g</sup>Department of Family Medicine, Oregon Health and Science University, Portland, Oregon

The authors have indicated they have no financial relationships relevant to this article to disclose.

## ABSTRACT

**OBJECTIVES.** Alternating hemiplegia of childhood is a predominantly sporadic neurodevelopmental syndrome of uncertain etiology. In more than 3 decades since its description, little progress has been made in understanding its etiology or in identifying effective treatments. In 1998, in collaboration with the Alternating Hemiplegia of Childhood Foundation, an international registry was established to help document clinical outcomes and promote research efforts.

**PATIENTS AND METHODS.** We present phenotypic data on 103 patients who met existing diagnostic criteria for alternating hemiplegia of childhood. Although some of these subjects may have been included in previously published reviews, our focus was directed toward the earliest manifestations of symptoms and evolution of features over time. Data sources included written questionnaires, face-to-face and telephone interviews, clinical examination, and medical charts. Characteristics of disease onset, medical comorbidities, episode triggers, diagnostic workup, and treatment are presented.

**RESULTS.** Paroxysmal eye movements were the most frequent early symptom, manifesting in the first 3 months of life in 83% of patients. Hemiplegic episodes appeared by 6 months of age in 56% of infants. Background slowing shown by electroencephalography during typical paroxysmal events, including hemiplegic, tonic, or dystonic episodes was frequent (21 of 42 cases). Distinct convulsive episodes with altered consciousness believed to be epileptic in nature were reported in 41% of patients. Ataxia (96%) and cognitive impairment (100%) were frequent nonepisodic symptoms. Empiric pharmacologic treatment approaches offered little benefit in most subjects and resulted in adverse effects in 20% of patients. Prolonged episodes were completely or temporarily aborted during sleep in all subjects.

**CONCLUSIONS.** This descriptive analysis of a large cohort of children indicates that paroxysmal ocular movements are an early, highly suggestive symptom, followed by paroxysmal episodes of focal dystonia or flaccid, alternating hemiplegia in early infancy in the majority of subjects. Current challenges in diagnosis and management contribute to poor outcomes. Early diagnosis and multicenter collaboration are needed to facilitate trials to identify more effective therapies. *Pediatrics* 2009;123:e534–e541

www.pediatrics.org/cgi/doi/10.1542/peds.2008-2027

doi:10.1542/peds.2008-2027

### Key Words

alternating hemiplegia, migraine, movement disorder, seizures, ocular movements

### Abbreviations

AHC—alternating hemiplegia of childhood  
FHM—familial hemiplegic migraine  
EEG—electroencephalographic  
SPECT—single-photon emission computed tomography  
PET—positron emission tomography  
MRA—magnetic resonance angiography  
MELAS—mitochondrial myopathy, encephalopathy, lactic acidosis, and stroke  
CSF—cerebrospinal fluid

Accepted for publication Dec 4, 2008

Address correspondence to Matthew T. Sweney, MD, University of Utah School of Medicine, 30 N 1900 East, SOM Room 3R413, Salt Lake City, UT 84132. E-mail: sweney@genetics.utah.edu

PEDIATRICS (ISSN Numbers: Print, 0031-4005; Online, 1098-4275). Copyright © 2009 by the American Academy of Pediatrics

**A**LTERNATING HEMIPLEGIA OF childhood (AHC) is a complex clinical entity initially thought to be a migraine variant. Verret and Steele first characterized the syndrome in 1971.<sup>1</sup> They described a series of 8 children with bouts of intermittent alternating hemiplegia in addition to other neurologic abnormalities, including developmental delay, choreoathetosis, and dystonia. Clinical features were refined in 1980<sup>2</sup> and again in 1993<sup>3</sup> to include 6 typical diagnostic criteria (Table 1).

Although incidence has been estimated at 1 in 1 000 000 births,<sup>4</sup> variability in clinical presentation, lack of awareness of the disease, and misdiagnosis may contribute to an underestimation of the true burden of disease. The evolving nature of the abnormal movements and their complexity, as well as the manifestation of comorbid generalized epileptic events in up to 50% of patients, further complicates the diagnosis.<sup>5</sup> Outcome in children with

**TABLE 1** Diagnostic criteria for classical AHC

Onset of symptoms before 18 mo of age
Repeated attacks of hemiplegia involving either side of the body
Other paroxysmal disturbances including tonic or dystonic spells, oculomotor abnormalities, and autonomic phenomena during bouts in isolation
Episodes of bilateral hemiplegia or quadriplegia as generalization of a hemiplegic episode or bilateral from the beginning
Immediate disappearance of symptoms upon sleeping, which later may resume after waking
Evidence of developmental delay and neurologic abnormalities including choreoathetosis, dystonia, or ataxia

AHC is often poor, with frequent episodes of paroxysmal neurologic impairment, as well as less severe but persistent motor disability and global developmental impairment in the majority of those affected<sup>3,5,6</sup>. Unfortunately, the current lack of understanding of etiology and pathophysiology, combined with a lack of proven effective therapeutic options, leaves patients and families desperate to try untested therapies, further enhancing the risk for poor outcome.

## PATIENTS AND METHODS

### Study Population

Database participants were enrolled with full institutional review board approval. Referral sources included collaborating physicians and AHC family support organizations in North America and France. Some patients were likely included in previous reviews; however, all data for this study were collected independently.<sup>3,5</sup>

From 1998 to 2007, 172 patients reporting episodic hemiplegia were enrolled. Data sources included medical charts, written questionnaires, and direct patient/family interview; clinical examinations were documented for >100 patients via participation in regional family conferences sponsored by the AHC Foundation (United States and Canada) and Association Française de l'Hémiplégie Alternante (France).

From an initial cohort of 172 patients, 132 had accompanying records considered sufficient for establishment of clinical phenotype, and 103 patients met existing criteria for AHC.<sup>3</sup> Of these, 56 were female and 47 were male, including a set of identical twins. Fourteen (7 male, 7 female) of 132 patients were considered atypical in that the onset of hemiplegic episodes occurred after 18 months of age; these cases were excluded from our analysis. Another 15 patients were found to have distinctly different clinical entities such as familial hemiplegic migraine (FHM) ( $n = 2$ ) and benign nocturnal familial AHC ( $n = 3$ ) or were part of affected families with atypical characteristics ( $n = 10$ ).

Of the 103 patients who met formal diagnostic criteria, we had information regarding ethnicity on 90 (including 82 white, 4 Hispanic, and 4 other). Nationalities represented included the United States ( $n = 65$ ), France ( $n = 23$ ), Canada ( $n = 5$ ), Israel ( $n = 2$ ), Sweden ( $n = 2$ ), India ( $n = 1$ ), Brazil ( $n = 1$ ), Czech Republic ( $n = 1$ ), Italy ( $n = 1$ ), the Netherlands ( $n = 1$ ), and the United Kingdom ( $n = 1$ ). Age at time of enrollment ranged from

6 months to nearly 30 years. Information obtained via questionnaires, interviews, medical charts, and examinations was organized into 5 specific categories: (1) disease presentation and characteristic episodes; (2) neurologic comorbidities; (3) event triggers; (4) diagnostic studies; and (5) treatment history.

Hemiplegia, quadriplegia, dystonic/tonic episodes, and paroxysmal oculomotor events were individually elicited when possible. Data on duration of episodes and associated epiphenomena (ie, temperature or color change, respiratory difficulty) were elicited. Presumed epileptic convulsive events, distinguished from other episodic events by an associated alteration of consciousness in conjunction with either sustained bilateral tonic or tonic-clonic activity, were recorded separately. Other coded neurologic comorbidities included ataxia, choreoathetosis, and cognitive impairment. Triggering events or environmental influences were delineated and grouped broadly into 5 categories: (1) stress or physical activity; (2) specific foods; (3) light sensitivity; (4) exposure to water (eg, swimming or bathing); and (5) medications. The diagnostic workups, with specific attention to electroencephalographic (EEG) and MRI findings, were documented, as were pathologic (muscle or skin biopsy), laboratory, and other radiologic studies (positron emission tomography [PET], single-photon emission computed tomography [SPECT], computed tomography, and magnetic resonance angiography [MRA] results). Medication history in relation to symptoms of AHC was also recorded.

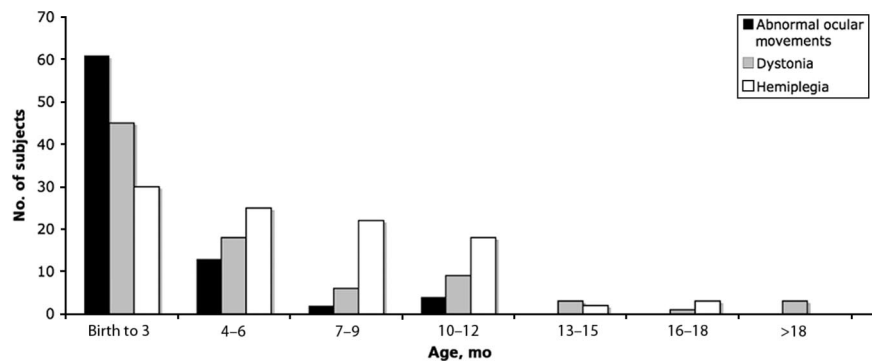
## RESULTS

For 103 patients who met clinical diagnostic criteria, average age of onset for hemiplegic or quadriplegic episodes was 6 to 7 months ( $6.6 \pm 4.3$  months), and the average age of onset for dystonic episodes was similar ( $6.4 \pm 11.4$  months) (see Fig 1). In 86 cases where specific age at onset was determined for dystonic episodes, 35 (41%) had dystonic symptoms before plegic episodes, and 30 (35%) had dystonic and plegic episodes with concurrent onset. Age at time of diagnosis was variable (range: 6–240 months), although the average was just over 36 months ( $36.5 \pm 48.7$  months). Age at the time of enrollment was also variable (range: 6–384 months), with a mean of nearly 108 months ( $107.5 \pm 87.8$  months). Forty-seven (46%) patients submitted records or were evaluated at more than 1 point after initial enrollment into the study.

There was an extremely broad range given for duration of typical dystonic or plegic episodes. For all patients, variable episode duration was reported, ranging from minutes to hours to days. Episodes >24 hours and up to 3 weeks in duration were reported for 38 (38%) subjects. Such prolonged episodes consisted of fluctuating, alternating hemiparetic and quadriparetic events without returning to baseline in between episodes.

Episodic abnormal eye movements were documented for 96 (93%) of 103 patients, with a mean onset of 2½ months of age ( $2.4 \pm 3.1$  months) (see Fig 1). In 31 (32%) of these 96 patients, abnormal eye movements were noted within 1 or 2 days of birth. The most frequently described paroxysmal eye movement abnormality was nystagmus

FIGURE 1  
Age of onset of symptoms of AHC.



(48 children, of whom 10 had clearly documented episodes of monocular nystagmus). Intermittent esotropia/exotropia or other monocular deviation was noted in 40 children. Parents frequently reported an evident change in respiratory pattern in association with episodes, with respiratory distress or frank apneic episodes documented for 25 (24%) children. Color or temperature change with episodes was reported for 60 (58%) patients.

Specific neurologic comorbidities were documented, including epilepsy, cognitive impairment, and the appearance of a persistent movement disorder. Forty-four (43%) of 103 patients reported repeated episodes of generalized tonic or tonic-clonic activity in association with an obvious alteration of consciousness thought to be clinically consistent with a diagnosis of epilepsy. In these children, such episodes were uniformly much less frequent than their other more "typical" episodic neurologic events. Given the relative infrequency of these events, and the perceived urgent need for intervention because of respiratory compromise, EEG documentation that such events were truly epileptic was usually lacking. Although we cannot exclude the possibility that such events represent severe bilateral tonic episodes in some children, the association of altered consciousness clearly distinguishes them from other episodes; EEG studies confirming that such events were truly epileptic were available for only a small subset of patients. The mean age of onset of epileptic events was nearly 6 years ( $68.6 \pm 58.0$  months), with 10 (23%) of the 44 cases not reporting onset until 10 years of age or later. In patients with available records, all (88 of 92) but 4 had ataxia, whereas cognitive impairment was present in every case with documentation (96 of 96). Impairment was generally described by families as mild to moderate. In a subset ( $n = 41$ ) of the affected children, neuropsychological evaluation performed by our group demonstrated high variability in functional impairment for cognitive, adaptive, and behavioral domains, with younger patients demonstrating more intact and functional cognitive and adaptive skills than older patients. Pooled data of that subset showed full-scale IQs (when using the Wechsler Abbreviated Scales of Intelligence) of  $62.5 \pm 14.0$ , with an average verbal IQ of  $69.2 \pm 15.9$  and performance IQ of  $63.7 \pm 15.4$ . Detailed analysis of these data will be reported separately.

Familial history of recurrent headache was reported

in 56 (54%) cases; however, only 17 case subjects reported first-degree affected relatives. General headache characteristics were not available for most family members; however, in 1 case, an affected subject's father was noted to have adult-onset migraine with transient hemiparesis. Seven (7%) patients had congenital hip dysplasia. Sudden unexplained death occurred in 3 patients over 10 years.

Triggering events were broadly categorized into several different areas including environmental stress, water exposures, specific physical activities, lighting changes, and foods (Table 2).

Review of diagnostic testing revealed that MRI study results were predominantly normal (54 of 69 cases with original documentation). Average age at the time of MRI (using most recent scans when multiples were available) was nearly 6½ years ( $77.09 \pm 66.58$  months). Generalized cortical atrophy was present in 3 case subjects: 2 older patients (aged 13 and 23 years) and a 14-month-old male infant. Isolated cerebellar atrophy was evident in an 11-year-old wheelchair-bound girl. Two patients with AHC who met classic diagnostic criteria had mesial temporal sclerosis on MRI. One of these children clearly demonstrated the complexities that can arise in determining the nature of specific episodes and the need for vigilance in reassessing patients as new symptoms arise. Within the first 3 years of her clinical course, no epileptiform activity had been demonstrated despite numerous telemetry studies. When she was restudied later because of the appearance of events distinct from her typical hemiplegic and dystonic episodes associated with altered consciousness, EEG studies revealed multifocal high-amplitude spikes and slow waves in the right hemisphere. However, electrographic discharges did not definitely

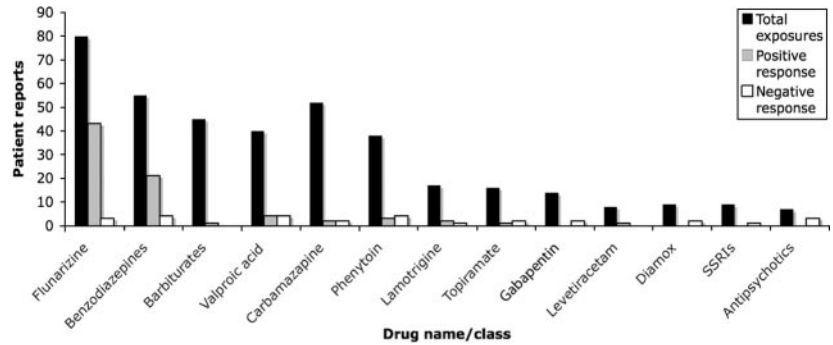
TABLE 2 Reported Triggers in AHC

Category	Cases Reporting, %	Examples
Environmental stress	75	Temperature extremes, crowds, odors, irregular sleep
Water exposure	61	Bathing, swimming, shampooing
Specific physical activities	50	Exercise, playground swing
Lighting	47	Sunlight, fluorescent bulbs
Foods	10	Chocolate, food dyes



FIGURE 2

Treatment exposures according to class in AHC. SSRIs indicates selective serotonin reuptake inhibitors.



correlate with any clinical events, and telemetry captured a period of right-sided hemiplegia associated with only with 2- to 4-Hz generalized background slowing.

EEG reports were available for review in 83 cases. For 42 patients, we had EEG reports that clearly documented the absence of epileptiform features during plegic or dystonic episodes. The remaining 41 cases had clinical notes referencing the absence of epileptiform activity on EEG testing but no additional documentation. Many EEG reports provided insufficient information to be instructive (eg, results were “normal” with no indication as to whether events were observed) or clearly documented the absence of hemiplegic or dystonic episodes during testing and, thus, were inconclusive. Twelve patients had focal sharp wave discharges not associated with plegia or dystonia. Two of these 12 patients (including the 3-year-old patient discussed above) received a secondary diagnosis of complex partial seizures. In both cases, seizure manifestations were distinctly unique from plegic and dystonic episodes, and medical charts indicated that previous EEG recordings had documented absence of epileptiform findings during such plegic and dystonic episodes. In 21 of 42 cases, patients were found to have background slowing, and in 15 patients, such slowing occurred intermittently during plegic or dystonic episodes. In the remaining cases for which clinical events were captured, there were no EEG abnormalities described.

SPECT ( $n = 36$ ) and 2- $[^{18}\text{F}]$ fluoro-2-deoxy-D-glucose (FDG) PET ( $n = 33$ ) scans were often performed on patients; however, only a small subset of these clinical reports was available. The most commonly reported findings were hypometabolism for both SPECT ( $n = 5$ ) and FDG PET ( $n = 5$ ). Normal angiographic studies were documented for 25 patients. Muscle and skin biopsy were frequently ( $n = 38$ ) performed to evaluate for possible mitochondrial abnormalities; however, in only 1 instance were abnormal findings reported (ie, complex III deficiency documented via testing on a frozen specimen). Various metabolic screening tests were performed on all patients at some point before diagnosis, and results were almost universally normal aside from nonspecific changes indicative of a catabolic state. Comprehensive screening for mutations in *CACNA1A* and *ATP1A2* was not performed; however, in a pilot study using comparative genomic hybridization (Human Genome CGH Microarray 244K [amadiid 14693] from Agilent Technol-

ogies [Santa Clara, CA]) in a subset of 10 subjects within this cohort revealed no evident mutations. Further investigation into the utility of this technology in relation to AHC is ongoing.

The most frequent pharmacologic treatment interventions were flunarizine ( $n = 80$ ), benzodiazepines ( $n = 55$ ), carbamazepine ( $n = 52$ ), barbiturates ( $n = 45$ ), and valproic acid ( $n = 40$ ). Flunarizine and benzodiazepines were more often associated with a perceived improvement in dystonic or plegic episodes: 48 of 80 of patients using flunarizine reported some benefit, whereas 21 of 55 reported an improvement with benzodiazepines (see Fig 2). No further characterization as to duration of effect or type of improvement was elicited; however, even those reporting improvement with a given treatment frequently expressed uncertainty regarding long-term impact on symptoms. Antipsychotics, selective serotonin reuptake inhibitors, gabapentin, and diamox were invariably not helpful. Of note, of 16 patients who received a trial of topiramate, only 1 had reported improvement, in contrast to recent case reports documenting clear improvement in frequency or severity of paroxysmal events. In all, 21 (20%) patients reported serious adverse responses to a prescribed medication resulting in its discontinuation. In addition, in 310 total drug exposures listed within our database, 28 (9%) resulted in frank worsening of symptoms associated with AHC, whereas only 84 (27%) were thought to have any benefit.

## DISCUSSION

Patients with AHC present significant challenges in diagnosis, management, and treatment. Although the time to diagnosis has improved in recent years, a surprising proportion ( $n = 16$ ) of patients in this review were  $>3$  years of age by the time the diagnosis was considered. Fortunately, the time to diagnosis seems to have improved when compared with previous estimations of 5 to 6 years.<sup>7</sup> One of the most surprising findings of the current review is the frequency of children manifesting symptoms in the neonatal period. Nearly one third of the subjects manifested episodic oculomotor features within 1 or 2 days after birth, and a substantial proportion manifested onset of hemiplegia and dystonia from birth to 3 months (see Fig 1). The predominantly infantile onset of symptoms, frequency of paroxysmal events, and high prevalence of associated neurologic and developmental impairments highlighted in this review are key

**TABLE 3 Screening Criteria for Early Suspicion of AHC**

Focal or unilateral paroxysmal dystonia and/or flaccid hemiplegia in the first 6 mo of life
Paroxysmal ocular movements including biocular and monocular nystagmus and/or deviation in the first 3 mo of life
Absence of epileptiform changes during ictal events

features that help to distinguish AHC from other episodic neurologic disorders.

Although the spectrum of clinical characteristics and disease progression in AHC is broad, particularly with regard to frequency and duration of plegic and dystonic episodes, identification of a recognizable pattern and progression of features may help to facilitate earlier diagnosis. This, in turn, will facilitate the opportunity for a more standardized approach to treatment trials. Episodic monocular nystagmus, an extremely unusual eye-movement abnormality, should immediately provoke consideration of this diagnosis. Bilateral nystagmus that is episodic in nature is also unusual, although nonspecific; however, when observed in association with unilateral posturing or obvious hemiplegia, AHC should clearly be considered. Part of the delay in suspecting the diagnosis rests in the currently used clinical criteria, which may be too specific, requiring the emergence of other static neurologic symptoms before clinicians feel comfortable in considering the diagnosis. Alternative, more simplified criteria are suggested in Table 3.

A significant challenge in the diagnosis of AHC is in distinguishing paroxysmal movement-disorder symptoms from clinical seizures, particularly if both types of episodes are present in the same patient. Admittedly, an infant who presents with abnormal eye movements and tonic stiffening is more likely to have an epilepsy syndrome. However, nonepileptic features on EEG results in the setting of observed dystonic or plegic events should immediately lead to consideration of this diagnosis. Because paroxysmal episodes may be more frequent and prolonged in infants with AHC compared with infantile epilepsy syndromes, it may be somewhat easier to capture nonepileptic plegic or dystonic events associated with AHC. Prolonged video EEG monitoring of  $\geq 12$  hours to enhance the likelihood of capturing episodes

may help to better characterize the paroxysmal manifestations of AHC and their EEG correlates. Such studies are an indispensable part of the diagnostic algorithm in such patients to exclude alternative phenotypes such as infantile-onset epileptic encephalopathies (see Table 4).

With time, however, an increasing percentage of patients manifest episodes suggestive of generalized epileptic events. In this cohort, 43% of typical cases reported concurrent epilepsy with AHC as evidenced by distinct tonic-clonic movements with loss of consciousness. This proportion is consistent with previous estimates.<sup>5,8</sup> However, on the basis of our findings, electrographic seizures are rarely captured, possibly because of later, less frequent, and less predictable occurrence. In any event, the potential morbidity added by a secondary epileptic component further exemplifies the significant complexities involved in confirming the diagnosis of AHC (with or without associated epilepsy) and in determining treatment approaches for the various manifest symptoms, both epileptic and nonepileptic.

The underlying disease mechanism in AHC remains unclear. Given the various and paroxysmal neurologic symptoms in AHC, it seems likely that a generalized cellular dysfunction of some sort is the basis for symptomatology. Previous studies that explored a mitochondrial etiology have been inconclusive<sup>9-11</sup> and are not supported by our data; however, similar paroxysmal neurologic events including hemiplegia can accompany metabolic disorders (including pyruvate dehydrogenase deficiency, mitochondrial myopathy, encephalopathy, lactic acidosis, and stroke [MELAS], and glucose-transporter defects<sup>12-14</sup>) and require exclusion before diagnosis can be made (see Table 4). In the majority of infants who present with AHC, abnormal eye movements precede development of other episodic neurologic phenomena. Similar episodic oculomotor abnormalities have been noted in neurotransmitter deficiency states such as aromatic amino acid decarboxylase deficiency<sup>15</sup> and inborn errors of bipterin synthesis<sup>16</sup>; thus, cerebrospinal fluid (CSF) studies are needed to exclude these disorders.

An underlying channelopathy or neurotransmitter receptor defect might explain the close parallels between

**TABLE 4 Appropriate Evaluation in Determining the Diagnosis of AHC**

MRI, MRA, and magnetic resonance spectroscopy	To exclude structural and vascular abnormalities (such as Moyamoya syndrome) and metabolic disorders such as MELAS, pyruvate dehydrogenase deficiency or creatine transport disorders
CSF neurotransmitter and pterin metabolites, methyltetrahydrofolate	To exclude potentially treatable disorder of dopamine biosynthesis or pyridoxal phosphate-responsive symptoms or folate-deficiency states in patients with paroxysmal dystonia and oculomotor abnormalities
Metabolic screening (urine organic acids, plasma amino acids, acylcarnitine, blood lactate and pyruvate, CSF lactate, thyrotropin, thyroxine, CSF and plasma glucose levels)	To exclude mitochondrial disorders (eg, pyruvate dehydrogenase deficiency, MELAS), periodic paralysis with thyrotoxicosis, or glucose transporter defects
12- to 24-h video EEG monitoring	To exclude epileptic causes for abnormal movements; periodic reevaluation indicated for new or evolving episodes or in case of failure to capture episodes
Genetic screening ( <i>CACNA1A</i> , <i>ATP1A2</i> , or <i>SLC1A3</i> sequencing/screening)	Low yield but may be appropriate in cases where onset is later in childhood (>2 y), ictal episodes are infrequent, family history of complex symptoms with migraine, or documented epileptiform events and cerebral edema on MRI

symptoms in AHC and other migraine syndromes such as FHM.<sup>17-19</sup> Episodes in subjects with AHC parallel those seen in migraine syndromes in many respects, including the character of the observed perfusion abnormalities documented on SPECT scans.<sup>20-23</sup> In addition, triggers common to typical migraine, including menses, chocolate, and fatigue, are common to patients with AHC, as is the symptomatic improvement with sleep. Similar gross structural changes seen in severe cases of FHM<sup>24</sup> and previously published cases of AHC<sup>24-26</sup> imply that cell death may occur in severe cases. Animal models have helped to clarify the physiologic processes involved in FHM. Using a *CACNA1A* knock-in mouse model, van den Maagdenberg et al<sup>27</sup> were able to show increased current density in cerebellar neurons, enhanced neurotransmission at the neuromuscular junction, and a reduced threshold and increased velocity of cortical spreading depression. Theories posing neuronal membrane dysregulation intuitively seem to address the multifocal aspects of AHC. Unfortunately, supporting evidence for a heritable, channel-based etiology in the majority of cases is lacking<sup>28,29</sup> despite candidate gene analysis confirming mutations in FHM genes in some atypical familial cases of AHC.<sup>30-33</sup> Within our own database, sequencing of such candidate genes (ie, *CACNA1A*, *ATP1A2*) in a subset of subjects with classic AHC has been unproductive to date (unpublished data).

Recent reports have suggested a possible microvascular etiology on the basis of findings on skin biopsy.<sup>34</sup> Although MRI/MRA imaging is warranted to exclude potential major vascular etiologies such as Moyamoya syndrome or vascular occlusion, such studies cannot definitively exclude involvement of small vessels.<sup>35</sup> However, autopsy data from 2 cases in our database have not revealed obvious large, medium, or small vessel pathology in the central nervous system.

In contrast to FHM and other migraine variants, clinical outcome in AHC is frequently poor because of the pervasive developmental delays and persistent frequent episodes manifested by children as they grow into adulthood. Anecdotal observations of profound developmental regression after prolonged epileptic and nonepileptic episodes, even those clearly not associated with hypoxia, hypoglycemia, or other evident secondary insults, raise concerns about the impact of individual events on outcomes. Although it is unclear whether improved symptomatic control of such episodes would result in improved outcomes with regard to overall development, effective therapeutic options that have a clear and sustained impact on the frequency and duration of spells would undoubtedly enhance quality of life. Proven therapies for amelioration of episode frequency and duration are extremely limited, and the long-term impact of apparently even the most broadly effective agent, flunarizine, is essentially unknown.<sup>36-40</sup> Even those medications considered to be most useful by clinicians and families, including flunarizine and the benzodiazepines, have yet to be evaluated in prospective, randomized, placebo-controlled trials.<sup>7,41-43</sup> Thus, at present, there is little to

no justification for the uniform initiation of any particular therapeutic agent for all patients with AHC.

The establishment of an international AHC registry and database provides an opportunity to better characterize clinical features, enhance collaboration, and pose questions about the evolution of symptoms and signs across a larger cohort of patients. It may also facilitate a much-needed, large-scale, prospective study into this disorder and promote clinical and research collaborations. Ongoing research efforts, family support information, and video footage of disease characteristics are available through our group's Web site (<http://medicine.utah.edu/neurology/research/swoboda>).

As a retrospective analysis, there are considerable limitations to our study. When available, medical charts were used to validate and characterize specific components of an individual's medical history. However, obtaining complete medical charts from parents who are burdened by the demands of a developmentally delayed child and who were often exasperated by a long, tortuous, often unsatisfying clinical course made complete data collection a significant challenge. Much of our data were obtained from parental interviews and questionnaires. Inherent in this approach is the potential for recall bias and inaccurate reporting, which is especially significant when considering the broad span of time covered in adolescent and adult patients as well as the high variability in presentation (eg, hemiplegia versus quadriplegia, paretic versus dystonic) and duration (ranging minutes to weeks) of plegic or dystonic episodes. In most cases, parental recall of disease onset was strikingly vivid, which leads us to believe that our characterization of typical disease presentation and early progression is reliable. However, recall of effects of medications and number of medication exposures is highly suspect and is a significant weakness of this analysis. Prospective collection of such data would be of great benefit to the community of those with AHC and their treating physicians and enhance our abilities to create meaningful collaborations to improve the care and treatment of these complex patients.

## CONCLUSIONS

AHC is a rare but devastating disease that is difficult to diagnose and even more challenging to treat. Symptoms associated with AHC have a profound impact on affected patients and families. Health resource utilization is substantial in this population, because frequent attacks result in dozens of inpatient admissions or emergency department visits in the course of a year. Empiric medication trials can negatively affect patient health with limited therapeutic gains, particularly when medications are added to an existing regimen, which in itself was already of unclear benefit. The complexity and severity of this disorder makes it imperative that new therapeutic options be explored, preferably in a placebo-controlled fashion. In addition, earlier detection and accurate diagnosis might afford the opportunity to alter what seems to be an unrelenting course.



## ACKNOWLEDGMENTS

This research was funded by the Alternating Hemiplegia of Childhood Foundation.

We offer our gratitude to the patients and families dealing with AHC and the many clinicians who referred patients and provided clinical information for these studies, including Jean Aicardi, Frederic Andermann, Eva Andermann, Stéphane Auvin, Blaise Bourgeois, Marie Bourgeois, Paul Casaer, Harry Chugani, Bernard Echenne, Uri Kramer, Denis Lamblin, Mohamad Mikati, Sergei Perelman, Jong Rho, Shlomo Shinnar, Athina Xaidara, and Sotiris Youroukos. We give special thanks as well to the support provided by the Alternating Hemiplegia of Childhood Foundation in the United States and the Association Française Hémiplégie Alternante in France, including Richard George, Lynn Egan, Sharon Ciccodicola, and Dominique Poncelin.

## REFERENCES

1. Verret S, Steele JC. Alternating hemiplegia in childhood: a report of eight patients with complicated migraine beginning in infancy. *Pediatrics*. 1971;47(4):675–680
2. Krägeloh I, Aicardi J. Alternating hemiplegia in infants: report of five cases. *Dev Med Child Neurol*. 1980;22(6):784–791
3. Bourgeois M, Aicardi J, Goutieres F. Alternating hemiplegia of childhood. *J Pediatr*. 1993;122(5 pt 1):673–679
4. Neville BG, Ninan M. The treatment and management of alternating hemiplegia of childhood. *Dev Med Child Neurol*. 2007;49(10):777–780
5. Mikati MA, Kramer U, Zupanc ML, Shanahan RJ. Alternating hemiplegia of childhood: clinical manifestations and long-term outcome. *Pediatr Neurol*. 2000;23(2):134–141
6. Sakuragawa N. Alternating hemiplegia in childhood: 23 cases in Japan. *Brain Dev*. 1992;14(5):283–288
7. Silver K, Andermann F. Alternating hemiplegia of childhood: a study of 10 patients and results of flunarizine treatment. *Neurology*. 1993;43(1):36–41
8. Bourgeois M, Aicardi J. The treatment of alternating hemiplegia of childhood with flunarizine: experience with 17 patients. In: Aicardi J, Andermann F, eds. *Alternating Hemiplegia of Childhood*. New York, NY: Raven; 1995:191–194
9. Kemp GJ, Taylor DJ, Barnes PR, Wilson J, Radda GK. Skeletal muscle mitochondrial dysfunction in alternating hemiplegia of childhood. *Ann Neurol*. 1995;38(4):681–684
10. Arnold DL, Silver K, Andermann F. Evidence for mitochondrial dysfunction in patients with alternating hemiplegia of childhood. *Ann Neurol*. 1993;33(6):604–607
11. Kyriakides T, Drousiotou A. No structural or biochemical evidence for mitochondrial cytopathy in a case of alternating hemiplegia of childhood. *Ann Neurol*. 1994;36(5):805–806
12. Head RA, Brown RM, Zolkipli Z, et al. Clinical and genetic spectrum of pyruvate dehydrogenase deficiency: dihydrolipoamide acetyltransferase (E2) deficiency. *Ann Neurol*. 2005;58(2):234–241
13. Klepper J, Leiendecker B. GLUT1 deficiency syndrome: 2007 update. *Dev Med Child Neurol*. 2007;49(9):707–716
14. Pavlakis SG, Phillips PC, DiMauro S, De Vivo DC, Rowland LP. Mitochondrial myopathy, encephalopathy, lactic acidosis, and stroke-like episodes: a distinctive clinical syndrome. *Ann Neurol*. 1984;16(4):481–488
15. Pons R, Ford B, Chiriboga CA, et al. Aromatic L-amino acid decarboxylase deficiency: clinical features, treatment, and prognosis. *Neurology*. 2004;62(7):1058–1065
16. Neville BG, Parascandalo R, Farrugia R, Felice A. Sepiapterin reductase deficiency: a congenital dopa-responsive motor and cognitive disorder. *Brain*. 2005;128(pt 10):2291–2296
17. Auvin S, Joriot-Chekaf S, Cuvelier JC, Vallee L. Familial alternating hemiplegia of childhood or channelopathy? A report with valuable pathophysiological implications. *Dev Med Child Neurol*. 2004;46(7):500; Author reply 501
18. Rho JM, Chugani HT. Alternating hemiplegia of childhood: insights into its pathophysiology. *J Child Neurol*. 1998;13(1):39–45
19. de Vries B, Stam AH, Beker F, et al. CACNA1A mutation linking hemiplegic migraine and alternating hemiplegia of childhood. *Cephalalgia*. 2008;28(8):887–891
20. Zupanc ML, Dobkin JA, Perlman SB. 123I-iodoamphetamine SPECT brain imaging in alternating hemiplegia. *Pediatr Neurol*. 1991;7(1):35–38
21. Kanazawa O, Shirasaka Y, Hattori H, Okuno T, Mikawa H. Ictal 99mTc-HMPAO SPECT in alternating hemiplegia. *Pediatr Neurol*. 1991;7(2):121–124
22. Aminian A, Strashun A, Rose A. Alternating hemiplegia of childhood: studies of regional cerebral blood flow using 99mTc-hexamethylpropylene amine oxime single-photon emission computed tomography. *Ann Neurol*. 1993;33(1):43–47
23. Wong V, Ho GC, Yeung HW, Ma KM. Alternating hemiplegia syndrome: electroencephalogram, brain mapping, and brain perfusion SPECT scan study in a Chinese girl. *J Child Neurol*. 1993;8(3):221–226
24. Takahashi T, Arai N, Shimamura M, et al. Autopsy case of acute encephalopathy linked to familial hemiplegic migraine with cerebellar atrophy and mental retardation. *Neuropathology*. 2005;25(3):228–234
25. Saito Y, Sakuragawa N, Sasaki M, Sugai K, Hashimoto T. A case of alternating hemiplegia of childhood with cerebellar atrophy. *Pediatr Neurol*. 1998;19(1):65–68
26. Yamashita S, Hamano S, Tanaka M, Yoshinari S, Minamitani M, Hayakawa M. Single photon emission computed tomography findings in a case of alternating hemiplegia of childhood in relation to migraine [in Japanese]. *No To Hattatsu*. 2005;37(5):413–418
27. van den Maagdenberg AM, Pietrobon D, Pizzorusso T, et al. A Cacna1a knockin migraine mouse model with increased susceptibility to cortical spreading depression. *Neuron*. 2004;41(5):701–710
28. Kors EE, Vanmolkot KR, Haan J, et al. Alternating hemiplegia of childhood: no mutations in the second familial hemiplegic migraine gene *ATP1A2*. *Neuropediatrics*. 2004;35(5):293–296
29. Haan J, Kors EE, Terwindt GM, et al. Alternating hemiplegia of childhood: no mutations in the familial hemiplegic migraine *CACNA1A* gene. *Cephalalgia*. 2000;20(8):696–700
30. Swoboda KJ, Kanavakis E, Xaidara A, et al. Alternating hemiplegia of childhood or familial hemiplegic migraine? A novel *ATP1A2* mutation. *Ann Neurol*. 2004;55(6):884–887
31. Mikati MA, Maguire H, Barlow CF, et al. A syndrome of autosomal dominant alternating hemiplegia: clinical presentation mimicking intractable epilepsy; chromosomal studies; and physiologic investigations. *Neurology*. 1992;42(12):2251–2257
32. Kanavakis E, Xaidara A, Papathanasiou-Klontza D, Papadimitriou A, Velentza S, Youroukos S. Alternating hemiplegia of childhood: a syndrome inherited with an autosomal dominant trait. *Dev Med Child Neurol*. 2003;45(12):833–836
33. Kramer U, Nevo Y, Margalit D, Shorer Z, Harel S. Alternating hemiplegia of childhood in half-sisters. *J Child Neurol*. 2000;15(2):128–130
34. Auvin S, Joriot-Chekaf S, Cuvelier JC, et al. Small vessel abnormalities in alternating hemiplegia of childhood: pathophysiological implications. *Neurology*. 2006;66(4):499–504
35. Gonzalez-Alegre P, Ammache Z, Davis PH, Rodnitzky RL.



- Moyamoya-induced paroxysmal dyskinesia. *Mov Disord*. 2003; 18(9):1051–1056
36. Di Rosa G, Spano M, Pustorino G, et al. Alternating hemiplegia of childhood successfully treated with topiramate: 18 months of follow-up. *Neurology*. 2006;66(1):146
  37. Jiang W, Chi Z, Ma L, et al. Topiramate: a new agent for patients with alternating hemiplegia of childhood. *Neuropediatrics*. 2006;37(4):229–233
  38. Wilson J. Treatment of alternating hemiplegia of childhood: the effect of haloperidol. In: Aicardi J, Andermann F, eds. *Alternating Hemiplegia of Childhood*. New York, NY: Raven; 1995:201
  39. Siemes H. Rectal chloral hydrate for treatment of alternating hemiplegia of childhood. In: Aicardi J, Andermann F, eds. *Alternating Hemiplegia of Childhood*. New York, NY: Raven; 1995: 203–204
  40. Siemes H. Rectal chloral hydrate for alternating hemiplegia of childhood. *Dev Med Child Neurol*. 1990;32(10):931
  41. Casaer P. Flunarizine in alternating hemiplegia in childhood: an international study in 12 children. *Neuropediatrics*. 1987; 18(4):191–195
  42. Casaer P, Azou M. Flunarizine in alternating hemiplegia in childhood. *Lancet*. 1984;2(8402):579
  43. Silver K, Andermann F. Alternating hemiplegia of childhood: treatment with flunarizine. In: Aicardi J, Andermann F, eds. *Alternating Hemiplegia of Childhood*. New York, NY: Raven; 1995: 195–198

## Alternating Hemiplegia of Childhood: Early Characteristics and Evolution of a Neurodevelopmental Syndrome

Matthew T. Sweney, Kenneth Silver, Marion Gerard-Blanluet, Jean-Michel Pedespan, Francis Renault, Alexis Arzimanoglou, Mylynda Schlesinger-Massart, Aga J. Lewelt, Sandra P. Reyna and Kathryn J. Swoboda

*Pediatrics* 2009;123:e534-e541

DOI: 10.1542/peds.2008-2027

<b>Updated Information &amp; Services</b>	including high-resolution figures, can be found at: <a href="http://www.pediatrics.org/cgi/content/full/123/3/e534">http://www.pediatrics.org/cgi/content/full/123/3/e534</a>
<b>References</b>	This article cites 39 articles, 12 of which you can access for free at: <a href="http://www.pediatrics.org/cgi/content/full/123/3/e534#BIBL">http://www.pediatrics.org/cgi/content/full/123/3/e534#BIBL</a>
<b>Citations</b>	This article has been cited by 2 HighWire-hosted articles: <a href="http://www.pediatrics.org/cgi/content/full/123/3/e534#otherarticles">http://www.pediatrics.org/cgi/content/full/123/3/e534#otherarticles</a>
<b>Subspecialty Collections</b>	This article, along with others on similar topics, appears in the following collection(s): <b>Neurology &amp; Psychiatry</b> <a href="http://www.pediatrics.org/cgi/collection/neurology_and_psychiatry">http://www.pediatrics.org/cgi/collection/neurology_and_psychiatry</a>
<b>Permissions &amp; Licensing</b>	Information about reproducing this article in parts (figures, tables) or in its entirety can be found online at: <a href="http://www.pediatrics.org/misc/Permissions.shtml">http://www.pediatrics.org/misc/Permissions.shtml</a>
<b>Reprints</b>	Information about ordering reprints can be found online: <a href="http://www.pediatrics.org/misc/reprints.shtml">http://www.pediatrics.org/misc/reprints.shtml</a>

American Academy of Pediatrics

DEDICATED TO THE HEALTH OF ALL CHILDREN™

